Renal

Facts:

- Retroperitoneal organ for homeostasis: detoxify and filter, balance pH, blood pressure
- Fibrous covering: Gerota fascia (surrounds kidney and adrenal gland)
- 2 main components to filter and then produce urine
  Parenchyma = Cortex and Medulla (Pyramids). Nephron is the functional unit. Cortex filters and pyramids absorb whatever the body wants to keep. What it doesn't = urine
  Sinus = Collecting system to remove urine

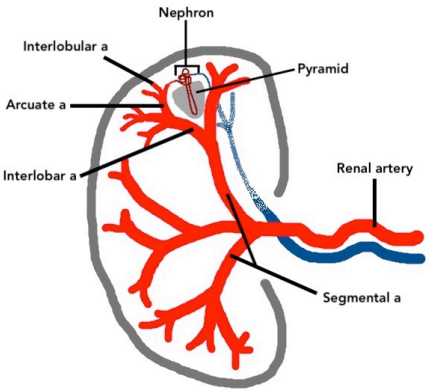

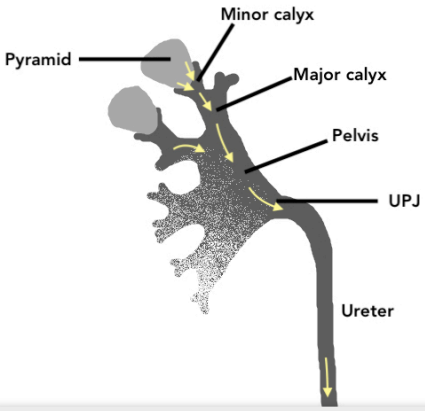

Filtering the blood

Arteries bring blood to the parenchyma

Renal Artery
⇓
Segmental
⇓
Interlobar
⇓
Arcuate
⇓
Interlobular
⇓
Nephron
⇓
Pyramid

Collecting system

Calices and pelvis drain urine

Minor calyx
⇓
Major calyx
⇓
Renal pelvis
⇓
Ureteropelvic junction
⇓
Ureter
⇓
Ureterovesicular junction
⇓
Bladder

Abdomen Registry Review
Study Guide

Anatomy

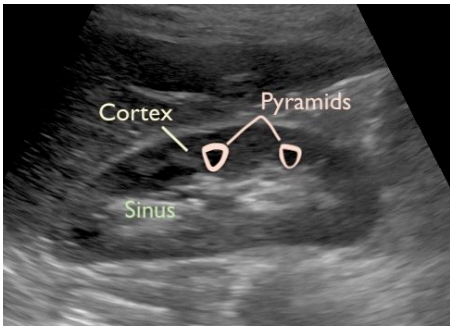

- Cortex forms outer rim = Hypoechoic compared to liver. Normal thickness >10mm
- Medulla is made up of pyramids = Hypoechoic compared to cortex. Columns of Bertin (cortical tissue) divide the pyramids
- Sinus = Hyperechoic due to fat content. Calices and pelvis is not seen if there's no fluid distending it

<u>Variants</u>

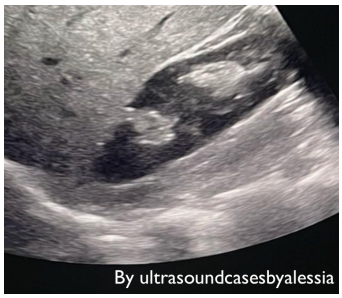

- Duplicated (duplex) collecting system: **Most common variant.** 2 renal sinuses divided by septum of cortex. Referred to as upper and lower moiety. Kidney may be longer and look like an 8. May cause hydronephrosis (usually lower moiety) due to ectopic ureter at UVJ
- Dromedary hump: Bulge on lateral border of left kidney
- Hypertrophic column of Bertin: Double layer of cortical column indenting into sinus
- Junctional parenchymal defect: Hyperechoic wedge shape along outer cortex
- Ectopic kidney: Failure to rise to renal fossa. Most likely in pelvis
- Horseshoe kidneys: Fusion of lower poles. Isthmus will cross anterior to aorta. Note image on right >>

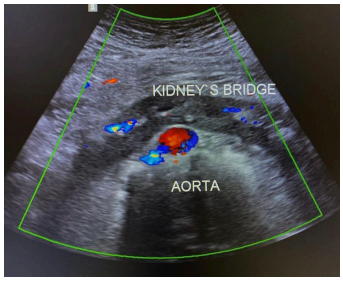

- Extrarenal pelvis: Renal pelvis outside the hilum. May mimic hydro
- Sinus lipomatosis: Increased fat in sinus, look bigger than normal
- Compensatory hypertrophy: "makes up" for what's not there. Unilateral conditions or anytime there is only one normal functioning kidney, the normal kidney becomes enlarged

Abdomen Registry Review
Study Guide

Intro to Pathology

Since the kidneys are made up into 2 parts = parenchyma and collecting system, we can divide the pathology into those 2 categories.

Parenchymal Functional part	**Collecting System** Series of tubes
Compromised renal function	Irritation
Tumors/Cysts	Obstructions and back-ups
Infections	Infections

Lab values and clinical history

- Compromised Renal Function
  Blood Urea Nitrogen (BUN) and creatinine. These are the renal "function" tests. Will be abnormal in diffuse, bilateral conditions that affect the parenchyma/nephron/cortex.
  Azotemia Elevated BUN/Creatinine and other symptoms of poor renal function such as hypertension and dec GFR (glomerular filtration rate).

BUN and Creatinine
Diffuse and Bilateral

- Urinalysis
  Current condition. Not overall function. The prefix tells us what is elevated in the urine

Pyuria = pus	INFECTION
Bacteriuria = bacteria	INFECTION
Hematuria = blood	DAMAGE (stones/tumors)
Proteinuria = protein	MASSES/INFECTION

- Collecting system pathology
  Similar to biliary disease (see page 15). Irritating, Blocking, Infections
  Irritating: stones = pain and hematuria
  Obstruction: stones/tumors = pain, hematuria and sono: dilated structures
  Infection = acute -itis. Symptoms are typical infection signs + py/bacteriuria

Acute Renal Failure

AKA acute kidney injury. **Most common cause acute tubular necrosis**. Sudden decrease in renal function, clinical more intense. Since initially appears normal, may be only a clinical diagnosis.

Clinical: Elevated BUN/creatinine, hypertension, oliguria, hypovolemia, edema

Sono: Initial normal (may only be clinical Dx), increased echogenicity of cortex

Chronic Renal Failure

Most common cause diabetes mellitus. Gradual decline in renal function due to damage of parenchyma.

Clinical: DM, elevated BUN/creatinine, hypertension, hyperkalemia (high potassium)

Sono: Small, echogenic kids, cortical thinning (<10mm), may have small cysts, loss of corticomedullary differentiation

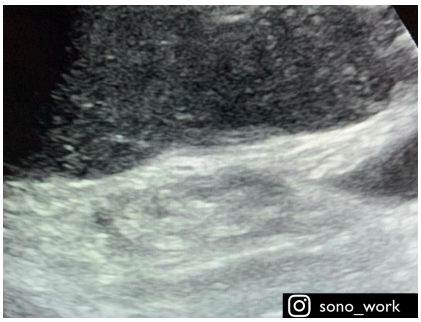

Corticomedullary differentiation

Pyramids (medulla) should normally be seen separate from cortex. In CRF, no longer see the difference between the cortex and pyramids

Cystic Conditions

Cystic diseases that affect renal function = cysts replace normal renal parenchyma. Bilateral will be related to poor renal function and symptoms

Autosomal Recessive PKD (infantile)

Congenital. Neonates ONLY. If survive to birth = already in renal failure.

Clinical: Elevated BUN/creatinine, renal failure clinical

Sono: Bilateral enlarged, echogenic (microcystic)

Autosomal Dominant PKD (adult)

Congenital. Develop cysts in mid-age (30's+). Gradual decline in renal function

Clinical: Elevated BUN/creatinine, poor renal function clinical

Sono: Bilateral enlarged, cystic kidneys

Multicystic Renal Dysplasia (aka Multicystic Dysplastic Kidney Disease)

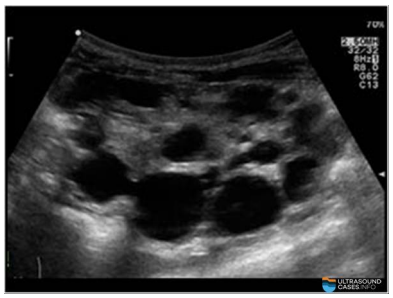

Congenital. If bilateral, FATAL. If seen, must be only unilateral. Although may look similar to PKD, there are 2 major difference. PKD is both kidneys and Multicystic is only one. PKD also has related clinical findings and this one does not

Clinical: NONE = unilateral condition

Sono: Unilateral cystic kidney, compensatory hypertrophy of contralateral kidney

Acquired Renal Cystic Disease

Caused by chronic hemodialysis = CRF patients

Clinical: Same as CRF

Sono: Small, bright + small cysts

Compare and contrast renal cystic diseases

ARPKD	ADPKD	Multicystic	Acquired
Neonates ONLY	Adults	Anyone	CRF/hemodialysis
Bilateral big & bright	**Bilateral big & cystic**	**Unilateral big & cystic**	**Bilateral small & cystic**
BUN/creatinine	BUN/creatinine	Normal	BUN/creatinine

Focal and Asymptomatic Conditions

Remember as long as the focal finding is not an abscess, blocking something, or producing hormones, there is NO associated clinical (no symptoms).

Cysts

Most common renal mass. Simple cysts are anechoic, smooth walls and posterior enhancement. Complex cysts (septations, internal debris, papillary projections) may be suggestive of malignancy

Multiple renal cysts may be associated with von Hippel-Lindau. Although NOT a renal condition, may cause multiple cysts in a variety of organs including kidneys.

- Exophytic: exo = outside. Project away from the kidney
- Cortical: arising from the cortex, larger will bulge outwards or distort contour
- Parapelvic: adjacent to pelvis, bulging inwards
- Peripelvic: arising from the inside of the pelvis, may mimic hydronephrosis or even cause it

PAR**A** = **Adjacent** to pelvis
PER**I** = **Inside** the pelvis

Cortical

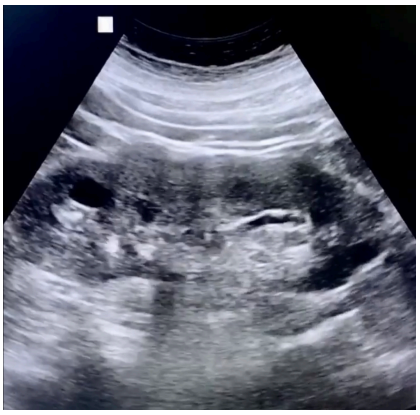

Parapelvic

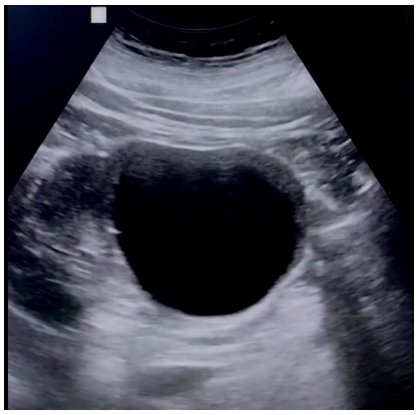

Cyst (cortical) on CT

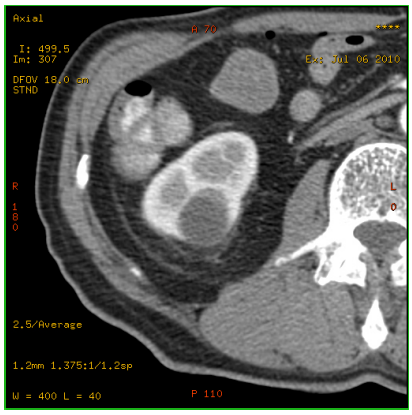

Angiomyolipoma

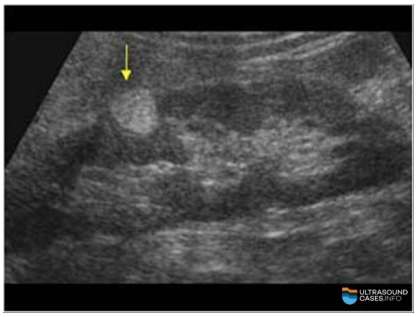

Aka Hamartoma. **Most common benign renal tumor.** Made up of blood vessels, muscle, and fat = echogenic and well-circumscribed If bilateral and multiple = tuberous sclerosis. Tuberous sclerosis is not a renal condition. Like von Hippel-Lindau, "side effect" is renal findings.

Mesonephric blastoma
AKA hamartoma
Most common benign renal tumor in pediatrics

Lipoma

Tumor made of fat. Similar appearance as AML

Hemangioma

Tumor made of blood vessels. Similar appearance as AML

Oncocytoma

2nd most common benign renal mass. Often found in older men. A stellate (star) shaped central scar with vascularity. Very similar to RCC, excision or biopsy necessary

Adenoma

Benign version of RCC, similar appearance. Excision or biopsy necessary

Hematoma

"Bleed" from trauma, surgery, lithotripsy

- Intraparenchymal: aka renal fracture. Hypoechoic within parenchyma
- Subcapsular: around the capsule
- Perinephric: in Gerota fascia
- Pararenal: anterior or posterior (see pg 2)

Clinical: Trauma or Biopsy Hx, decreased hematocrit, pain

Sono: Anechoic to echogenic depending on age. Old hematomas may calcify and shadow

Nephrocalcinosis and Medullary Sponge Kidney

Accumulation of calcium in the parenchyma. Cortical and Medullary
Medullary nephrocalcinosis (most common type) happens with the pyramids absorb too much calcium.

- Acquired: Caused by hypercalcemia and hyperparathyroidism. Parathyroids control level of calcium in blood. Overactive parathyroid or adenoma leads to hypercalcemia. Pyramids absorb the calcium
- Congenital: "Medullary sponge kidney" collecting tubules of pyramids are dysplastic eventually leading to calcium deposits

Sono: Medullary both types appear the same: echogenic pyramids

Cortical nephrocalcinosis : calcium deposits (small echogenic foci) diffusely within the cortex

Infection

Key symptoms when acute or active: Fever, leuko, pain.

Acute Pyelonephritis

Pyelo = pelvis. This is an infection of the collecting system. **Most common cause: ascending UTI from bladder.** Started in bladder, traveled up through the ureters, and now in kidney

Clinical: Bacteriuria, pyuria, dysuria, flank/back pain, fever, etc

Sono: Initially normal, may have regions of altered echogenicity

Complications

- Pyonephrosis: pus, or purulent material, dilating the collecting system
- Perinephric abscess: focal collection of pus adjacent to kidney
- Emphysematous pyelonephritis: Emphysema = air!!
  Air or gas bubbles produced by bacteria in the parenchyma.
  Who at risk: Diabetics and immunocompromised
  Sono: Reverberation (comet-tail / ring down) or dirty shadow

Chronic Pyelonephritis

Recurrent infections or chronic obstruction may lead to damage. Chronic -itis always indicates a damaged organ because of previous infections. Over time causes scarring of collecting system and renal atrophy. Pediatrics with vesicoureteral reflux (VUR) are also at risk

- Xanthogranulomatous Pyelonephritis
  Specific type of chronic in which renal tissue is damaged, formation of parenchymal granulomas and staghorn calculus within the pelvis

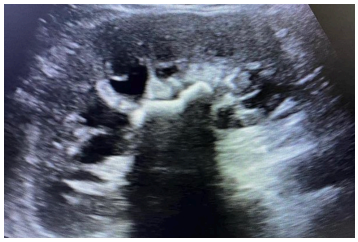

Clinical: May still present with some infection symptoms

Sono: Small, lobulated kidneys. May have scar from sinus through parenchyma with hydro

Glomerulonephritis

Glomerule is part of the functional nephron (like the capillary of the nephron). This infection starts in the parenchyma and is **most often caused by a throat (strep) infection**, or other distant infection. Infection travels through blood, settles into the kidney.

Clinical: Acute infection symptoms + hx of sore throat, hematuria, proteinuria, hypertension/azotemia if bilateral

Sono: Acute = enlarged kidney with echogenic cortex and prominent pyramids
Chronic would look the same as any chronically damaged kidney: small and bright

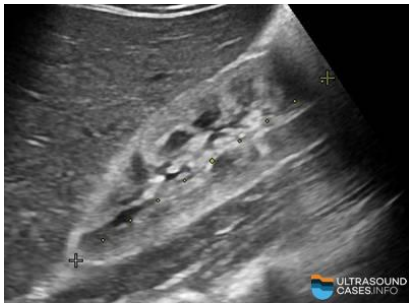

Fungal UTI

Most common cause is Candida albicans. Patients that are immunocompromised, diabetics, and that have in-dwelling catheters are increased risk.

Sono: Fungal balls within pelvis/collecting system

Parasitic UTI

Most common is schistosomiasis. In cases of recent travel. May also form a hydatid cyst

Abdomen Registry Review
Study Guide

Cancer

Renal Cell Carcinoma

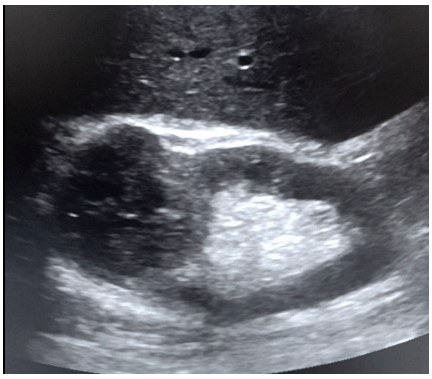

AKA hypernephroma. **Most common renal cancer. Most common solid renal mass** (in other words, assumed and more likely to be cancer unless it's a classic AML).

- Risk factors: Smoking, hypertension, chronic renal disease

  Clinical: Hematuria (damaged parenchyma), weight loss, pain

  Sono: Hypo, iso, hyperechoic mass. May present as complex cyst

  *** Check IVC for tumor invasion. Spreads via the renal veins

Transitional cell carcinoma

Most common cancer of bladder. May be found in kidney, arises from urinary tract (collecting system) so most likely located in renal pelvis.

Clinical: Hematuria, urinary obstruction

Sono: Mass within sinus, hydronephrosis or caliectasis

Pediatric tumors

Nephroblastoma AKA Wilms tumor

Most common solid malignant abdominal mass in peds. Usually <5yo. Similar to RCC in adults.

Clinical: Hematuria (damaged parenchyma), weight loss, pain

Sono: Solid heterogeneous mass

*** Check IVC for tumor invasion. Spreads via the renal veins

Vascular

Renal arteries originate inferior to SMA from anterolateral surface of Ao. Renal veins travel anterior to renal arteries

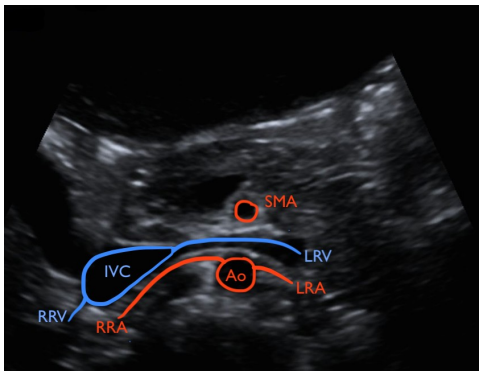

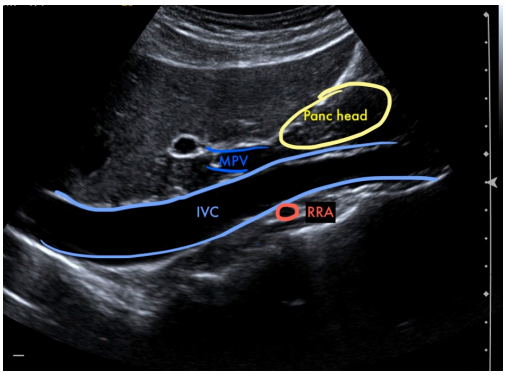

- Left renal vein crosses anterior Ao and posterior to SMA. Best landmark for left renal artery
- Right renal artery crosses posterior to IVC
- Most common renal vascular variation: duplicate renal arteries. Will follow same path as normal renal artery (right will both be seen post to IVC)

Renal artery stenosis

Most commonly caused by atherosclerosis.

Clinical: Hypertension without typical cause

Renal artery stenosis ⇒ Renal ischemia ⇒ Renin ⇒ Hypertension

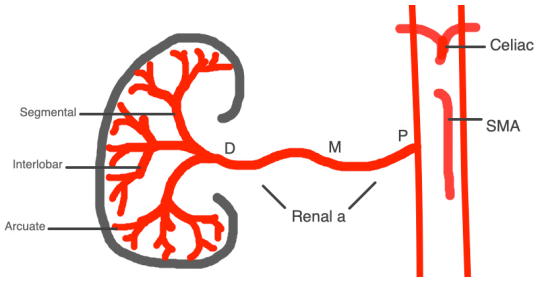

Protocol: in addition to performing a renal ultrasound, the following segments much be sampled with PW doppler

- Prox to distal renal artery
- Segmental artery (in sinus)
- Aorta just proximal to renal a.

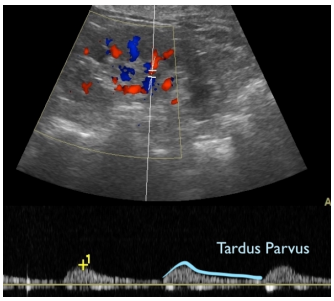

- Criteria: RAR Renal Aorta Ratio ≥3.5 ≥60%DR
  Tardus parvus waveform distal to stenosis at segmental artery
  - *Acceleration time measured onset of systole to peak systole*

Renal perfusion

Can be documented by doppler of the intraparenchymal arteries : segmental, interlobar, and arcuate arteries.

Normal: low resistance, sharp peak/dicrotic notch, high end diastolic flow RI <0.8

Nephrosclerosis: Intraparenchymal vessels will demonstrate increased resistance patterns

Nutcracker syndrome

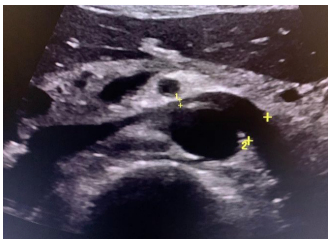

AKA renal vein entrapment. Compression of the left renal vein by SMA and aorta. May cause congestion and/or thrombosis of left renal vein.

Clinical: may have left sided flank pain, testicular pain, left varicocele

Renal Transplants

"Allograft" Placed most often RLQ, donor artery and vein is anastomosed to external iliac artery and vein. Donor ureter is attached directly to bladder. Most patients will still have native non-functioning kidneys, these should be documented as well to rule out development of tumors/cancer.

- Normal: renal tissue dopplers should be same as normal native kidney. RI <0.8
- Renal artery stenosis: **Most common vascular complication** (same findings as pg 39)
- Renal vein thrombosis: bidirectional, "to and fro" signal
- Rejection: although appearance may also be altered, most important is changes to resistance of arterial waveform

  Clinical: Signs of renal failure, anuria, azotemia, hypertension

  Sono: elevated resistance arterial patterns (hi resistance / less EDV), "thumping pattern"

3 abnormal renal vascular patterns and meanings

Renal artery stenosis	Renal vein thrombosis	Transplant Rejection
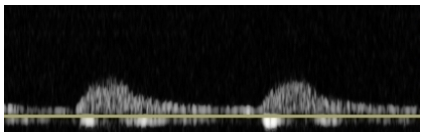	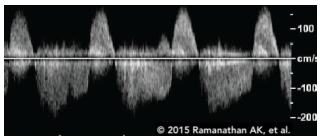	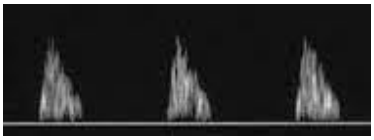
Tardus parvus	**Bidirectional**	**High resistance**

Urinary Tract Obstructions

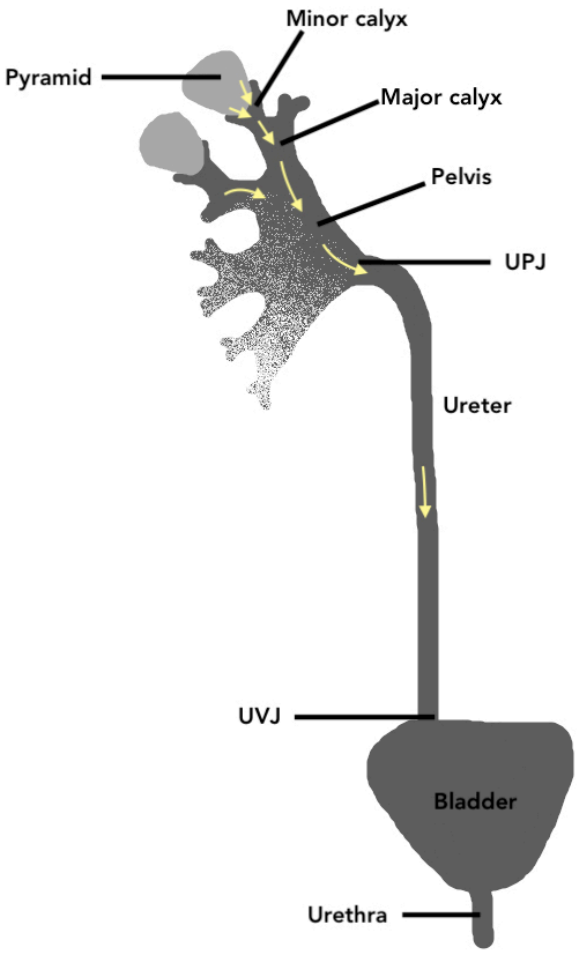

Similar to biliary tree, obstruction is a blockage and will cause dilatation proximal to (above) the location of the blockage. Blockage will be distal to (below) the dilated structures. So it's important to know the flow of urine, so you can understand the order of the back up in the case of blockage.

Terms to describe hydronephrosis
-ectasis = dilatation

Caliectasis = dilatation of the calices
Pelviectasis (pyel) = dilatation of the pelvis
Pelvocaliectasis = dilatation of the pelvis and calices

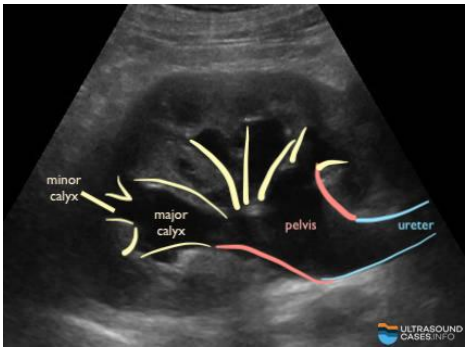

- **UPJ** Ureteropelvic junction. **Most common congenital location for pediatrics**
  Dilatation of renal pelvis, hydronephrosis only
- **UVJ** Ureterovesicular junction. **Most common location for adults (stone stuck)**
  Dilatation of ureter, then eventually hydronephrosis
- **Urethra** Bladder outlet obstruction (tumor, BPH)
  Dilatation of bladder, both ureters, and then eventually hydronephrosis.

Documentation of urinary jets into bladder can help determine presence of obstruction of ureter. Normal jets occur at least 1x per minute

Urolithiasis

Kidney stones that are located anywhere within the urinary tract. Nephrolithiasis refers to stones within the kidney.

- Non-obstructive stones may asymptomatic
- Staghorn calculus fills the renal pelvis (image right). May be related to recurrent UTIs and xanthogranulomatous pyelonephritis
- Obstructive will cause pain, hematuria and dilated structures. **Most common location for obstructive stone is the UVJ**, causing dilatation of the ureter and hydronephrosis

  Clinical: Depends on location and if obstructive

  Sono: Echogenic focus with posterior shadowing. Twinkle artifact may help identify smaller stones

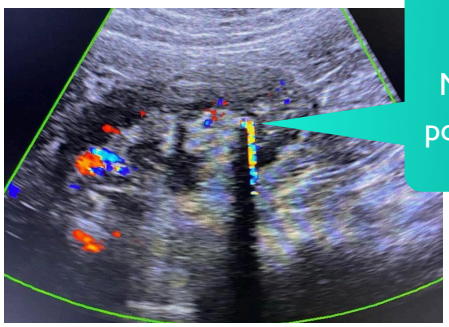

Twinkle artifact

Mosaic pattern color signal posterior or deep to calculus

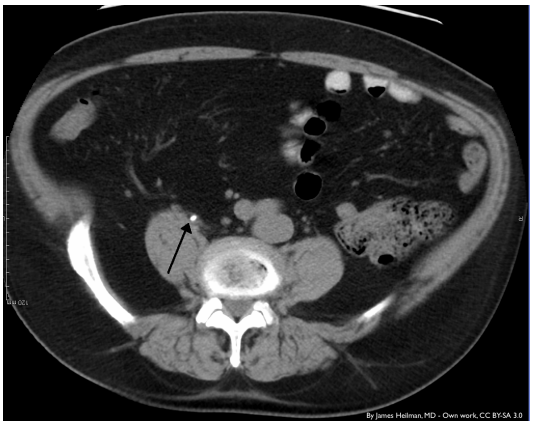

On CT kidney stones can be identified as hyper-dense or hyperechoic foci, similar to the brightness of bones

Ureterocele

Balloon-like cystic dilation of the attachment of the ureter to the bladder. Often associated with ectopic ureter locations such as with duplicated collecting systems. May cause urinary stasis, hydroureter, and UTI's

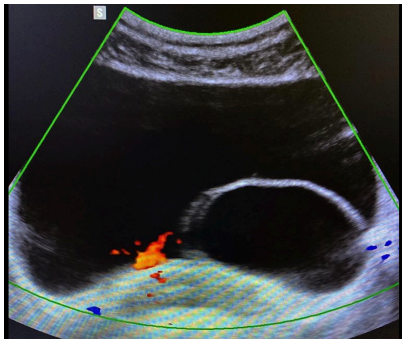

Hydronephrosis on CT

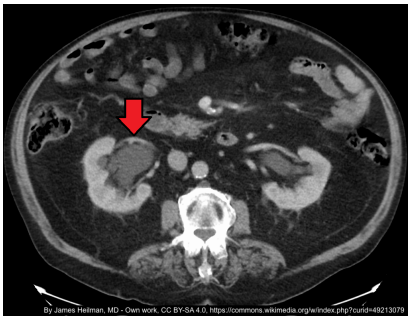

Similar to renal cysts, hydro will be darker grey. But the location of the fluid is arising out of the renal pelvis (on the medial side), will not have circular borders, and will make the kidney "widen"

Other causes of hydronephrosis

- Intrinsic: from the inside. Stones, tumors, bad ureteral valves, ureterocele
- Extrinsic: outside the urinary tract. Prostatic enlargement, pregnancy, abdominal/pelvic masses, retro fibrosis, basically that can compress or damage the outside of the ureters
- False positive: False appearance of a distended renal pelvis. Overly full bladder, extrarenal pelvis, prominent vascular structures, pelvic cysts

Pediatric congenital hydronephrosis

Urinary tract obstructions can be found at any level. All causes for urinary stasis will increase present with recurrent UTI's

- **Most common is UPJ** causing hydronephrosis only, ureter will be normal
- Vesicoureteral reflux (VUR): Urine flows backwards up into ureters due to abnormal valves. Grading of VUR is dependent on extent of renal pelvis and calyx dilatation. The ureter will be the first thing to dilate, termed hydro or megaureter (image right)

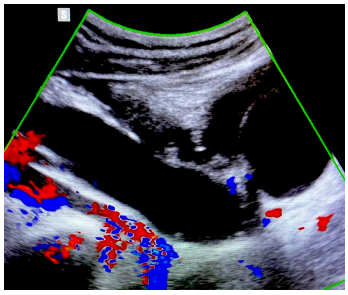

- Male babies can be born with posterior urethral valves causing prune belly syndrome. In utero, the fetus cannot empty bladder. Bladder dilates and urine back ups to kidney, damaging urinary tract.

UPJ obstruction	VUR	Posterior Urethral Valve
Most common congenital **Hydronephrosis only**	Recurrent UTI / dup kidney **Hydroureter and hydronephrosis**	Male / found in utero **Bladder, ureters, and hydronephrosis**

Bladder Pathology

Cystitis

Bladder wall thickening >4mm when bladder is distended. Most common in women and will present as an UTI

Neurogenic

Non-functioning bladder wall due to nerve damage or disorder. The bladder will be huge, pre and post void. Bladder volume L x W x H x 0.56

Clinical: No need to urinate

Sono: Large post-void residual volume, bladder wall thickening with trabeculae

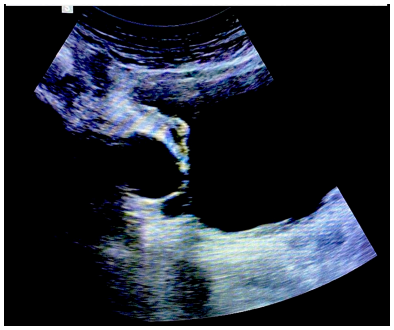

Diverticulum

Balloon like outpouching of bladder wall with distinct neck

Transitional cell carcinoma

Most common malignancy of bladder. Depending on location and size, may also be cause of urinary tract obstruction

- Intraluminal objects may be stones or blood clots. Change patient position to prove lack of mobility. Clots will look similar but will be mobile

  Clinical: Hematuria, may have urinary obstruction

  Sono: Papillary mass projecting from bladder wall, non-mobile, often demonstrate vascularity

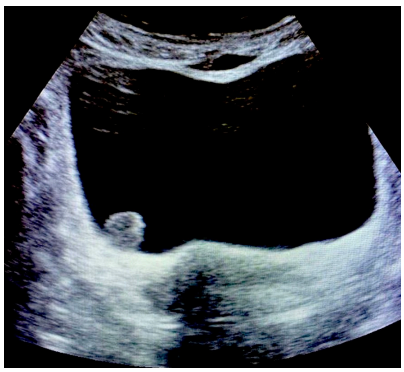

Adrenal glands

Facts:

- Retroperitoneal AKA suprarenal glands. Enclosed in Gerota fascia with kidneys
- Endocrine gland (hormones) controlled by pituitary gland
  Metabolism, immune system, response to stress

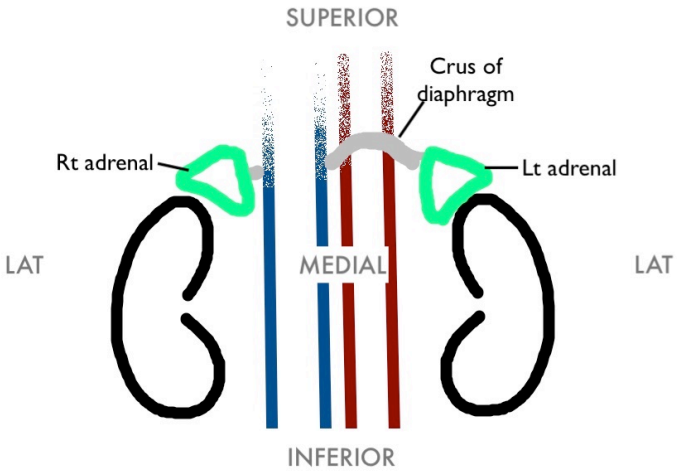

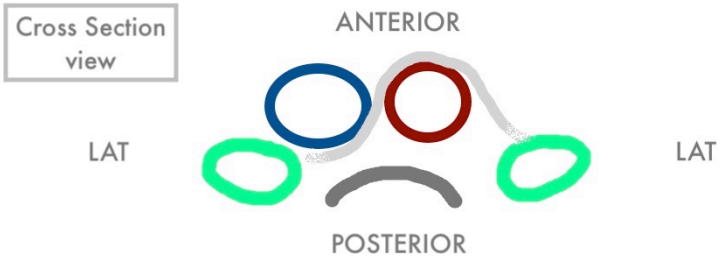

Anatomy and Location

- Supplied by suprarenal arteries
- Most posterior, just lateral to great vessels.
- Superomedial to kidneys
- On back wall (posterior), sandwiched between UP of kidney and great vessel
- Lateral to crus of diaphragm

Normal adult adrenals are not typically visualized. But location is important for pathology when identifying adrenal origin

Pediatric normal adrenal gland: hypoechoic outer cortex, echogenic inner medulla. Often pyramid or wishbone shaped

- Hypothalamus to pituitary to adrenal
  - Cortex (outer) Aldosterone / Androgens / Cortisol
  - Medulla (inner) Epinephrine / Norepinephrine

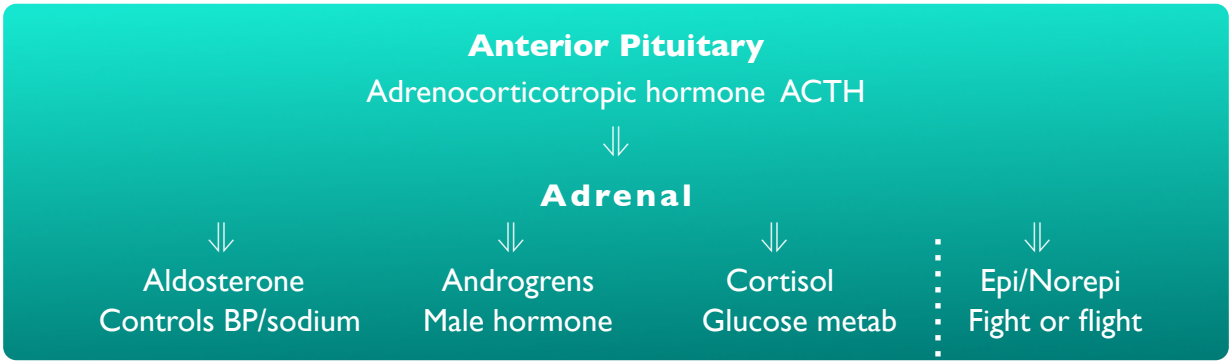

Pathology

Addison Disease

Primary adrenocortical insufficiency AKA chronic primary hypoadrenalism. Caused by autoimmune disease or infection. Gland is damaged = hypofunction

Addi**s**on
Adrenal **I**nsufficiency

- Pituitary gland will send more ACTH to try and stimulate the adrenals. So low adrenal hormones but high ACTH

  Clinical: Hypotension, weakness, fatigue, bronzing of skin, hyperkalemia (high potassium), hyponatremia (low sodium), inc ACTH

  Sono: Adrenal enlargement, possible calcifications

Functional pathology

Since adrenals are endocrine glands, most tumors will be symptomatic based on the hormone that is increased

Adrenal…	**Cortex** "A and C"	**Medulla**
Hormones	Aldosterone Androgens Cortisol	"Fight or Flight" Epinephrine Norepinephrine
Tumor	Adenoma	Pheochromocytoma
Disease	Conns or Cushings	

Adenoma

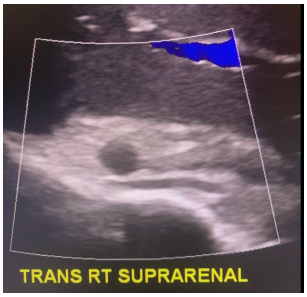

Most common benign solid mass of adrenal. Cortical tumor. If hyperfunctioning, will cause Conn or Cushing syndrome.

Sono: Solid, hypoechoic mass

The following are hyperfunctioning conditions if patient has been diagnosed with these clinically, then we are looking for an adenoma

- Cushing Syndrome
  Hypercortisolism. Too much cortisol. Cortisol helps regulate glucose metabolism. May be caused by adenoma.

  Clinical: Hypertension, obesity, buffalo hump, round moon shaped face, hirsutism, hyperglycemia (high sugar), purpura streaks (purple marks)

Cushing "Cushion"
Imagine someone with a cushion around their waist

- Conn Syndrome
  AKA primary hyperaldosteronism. Too much aldosterone. Aldosterone regulates blood pressure by controlling sodium/water ratio in body. May be caused by adenoma

  Clinical: Hypertension, thirsty, urinary frequency, hypernatremia (high sodium), hypokalemia (low potassium)

Pheochromocytoma

Hyperfunctioning medullary tumor. Too much epinephrine and norepinephrine, like a constant adrenaline rush.

Clinical: Uncontrollable hypertension, tachycardia, tremors, sweating, headaches, anxiety

Sono: Large, hyperechoic, may be heterogeneous

Adrenal Rests: Ectopic or accessory adrenal tissue. Can be found on testicles, may have signs of hyperfunction

Adrenal Carcinoma: Rare in adults. Typically will present with Cushings.

Pediatrics

Neuroblastoma

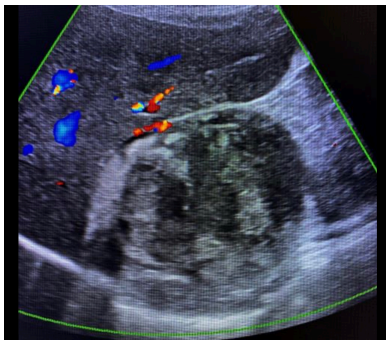

Most common extracranial malignancy in pediatrics. It's the most common "extracranial" because technically it can be in any location as it's a nervous system cancer. The most common location is the adrenal glands. Often with liver mets on discovery

- Usually young peds <5yo and metastasis on discovery.

  Clinical: Palpable mass, pain, may be related to Beckwith-Wiedemann

  Sono: Large heterogeneous mass, liver metastasis

Neuroblastoma
Most common EXTRACRANIAL cancer in pediatrics

Nephroblastoma
Most common ABDOMINAL cancer in pediatrics

Adrenal Hemorrhage

Spontaneous hemorrhage in stressed neonates, especially after traumatic birth or perinatal anoxia.

Clinical: Neonate, dec hematocrit, drop in BP

Sono: Varied echotexture depending on age

Abdomen Registry Review
Study Guide

Abdominal Vascular

Arterial Anatomy

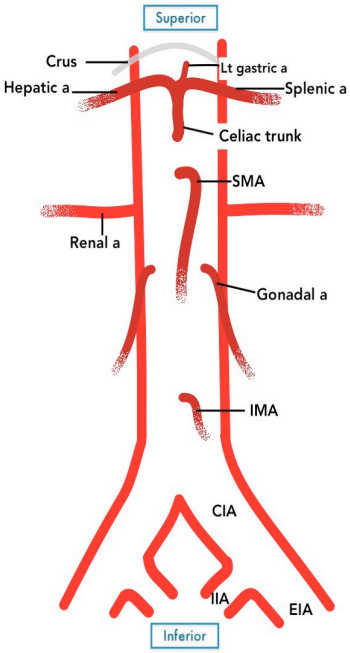

- Abdominal aorta originates at the crus of the diaphragm
- First branch is the celiac artery/axis/trunk
  From the celiac, arises the common hepatic, left gastric and splenic arteries. "seagull" sign in TRV view shows the celiac trunk with the 2 branches CHA and splenic artery.
- Superior mesenteric artery (SMA) arises inferior to celiac artery
- Renal branches just distal or below the SMA
  Renal arteries are posterior to veins. RRA is post/deep to IVC
- Other arteries arise inferiorly but not typically seen on US: gonadal and inferior mesenteric arteries

Sagittal midline Ao

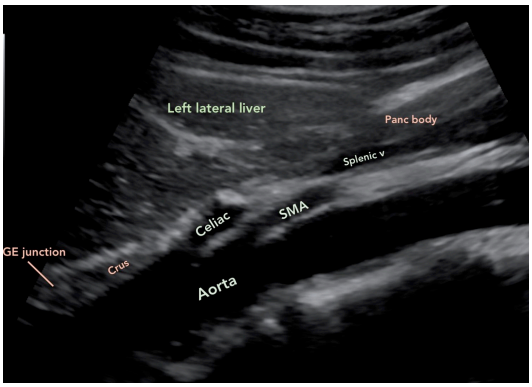

Sagittal right IVC

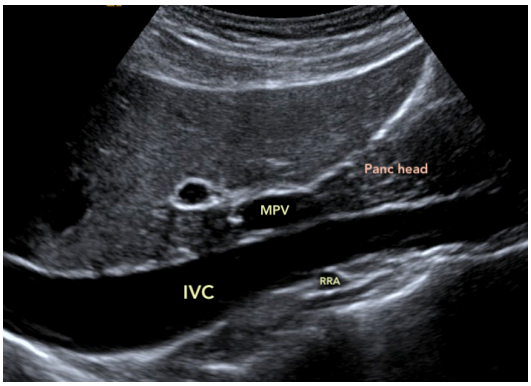

Transverse celiac trunk (sup to SMA)

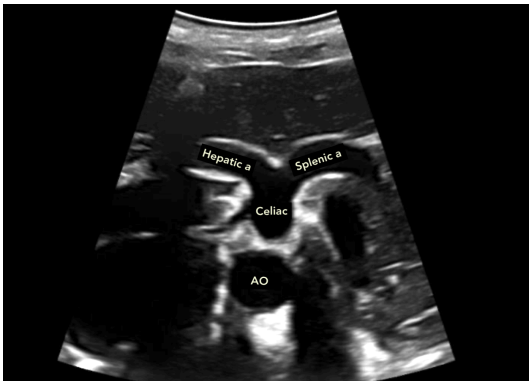

Transverse panc region (inf to celiac)

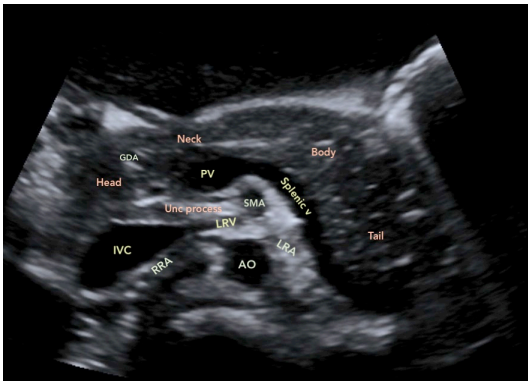

Abdomen Registry Review
Study Guide

Microscopic anatomy

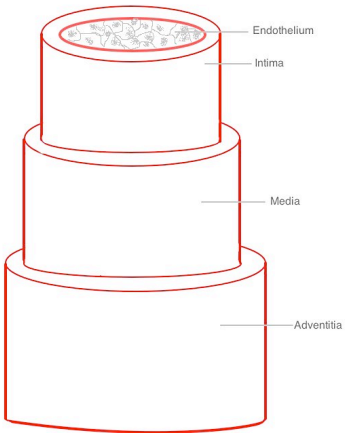

Intima: Thin innermost, covered by endothelium

Media: Thickest layer, smooth muscle and connective tissue

Externa/Adventitia: Outer, fibrous connective tissue. Contains vasa vasorum, tiny vessels that supply blood to vessel walls.

Arterial flow patterns

Normal flow patterns is dependent on what it is supplying. Organs requires constant perfusion (flow). So any artery feeding an organ will be LOW resistance. Low resistance means more volume flow. The greater the diastolic flow, the lower resistance. The less diastolic flow there is, the higher the resistance and pulsatility.

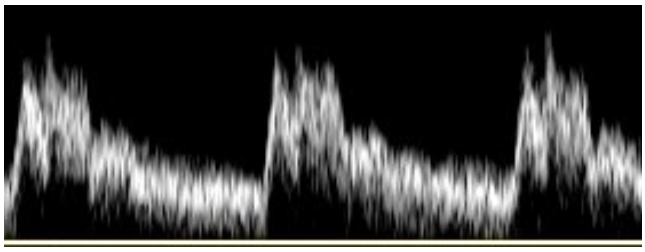

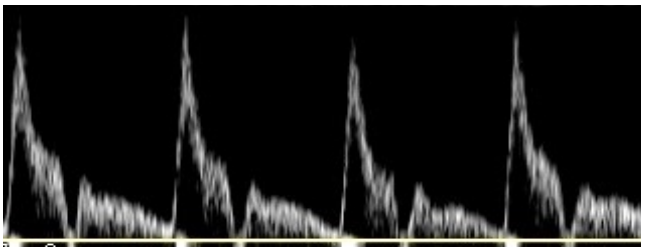

Low Resistance

Increased end diastolic velocity
Decreased resistive index
Decreased pulsatility index
Decreased impedance

Celiac trunk
Hepatic artery
Splenic artery
Renal arteries
Post-prandial SMA

High Resistance

Decreased end diastolic velocity
Diastolic flow reversal
Absent diastole
Increased resistive index
Increased pulsatility index
Increased impedance

Infrarenal aorta
Iliac arteries
Fasting SMA

Abdomen Registry Review
Study Guide

Arterial Pathology

Abdominal Aortic Aneurysm

AAA = Greater than 3cm. True aneurysm is when all 3 layers are dilated. **Most commons for AAA: type is fusiform, location is infrarenal, cause is atherosclerosis.**

Clinical: Abdominal / back pain, bounding abd pulsation

Sono: Dilatation >3cm, may have internal thrombus

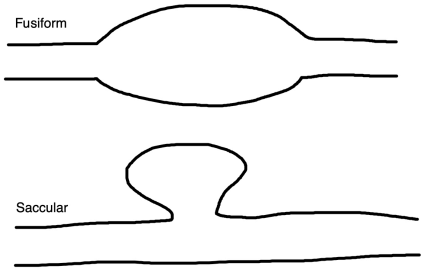

- Fusiform: overall vessel enlargement. Most common
- Saccular: sac-like dilatation or outpouching of the aorta
- >6cm: high risk of rupture, critical report needed
- Iliac arteries Normal: 1.0 - 1.2cm

Measuring the Aorta

It's important when measuring aorta and especially when aneurysm is present that the true lumen is measured in A/P outer to outer wall and perpendicular to the axis of the aorta, as properly indicated by the yellow dotted line in the image to the right.

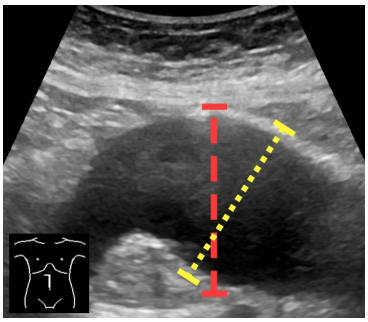

Aortic Dissection

Separation or tear of intima from the medial layer

- Marfan syndrome: weakening of walls, increased risk of aneurysms and dissections

Clinical: Severe abdominal, chest, and back pain

Sono: Intimal flap or lining floating inside the aorta

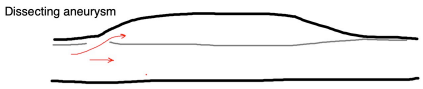

Pseudoaneurysm

Puncture through all 3 layers creating a pulsating hematoma connected by a neck or channel to the native artery. Most likely following procedure (angio or cath) or trauma

Sono: Pocket of swirling blood with communicating channel or neck to artery. Bidirectional flow/ to and fro pattern

Arteriovenous Malformation/Fistula

Connection between artery and vein most often following trauma or interventional procedures. Flow patterns will be high velocity and turbulent through the connection with arterial-like and pulsatile waveform of the outflow vein.

Urgent notifications

Life threatening conditions or pathologies needing immediate intervention must be reported to physician as critical finding.

Examples: AAA >6cm, signs of rupture, dissection, PSA, AVF

Mesenteric Ischemia

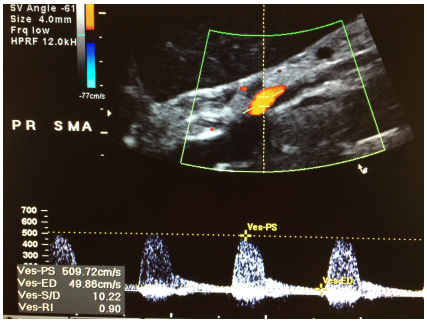

Arterial obstruction in the arteries that supply the gut : celiac trunk and SMA. Signs of arterial stenosis includes elevated velocities and spectral broadening. Waveforms may be abnormally high resistance in the presence of a distal obstruction. IMA may be dilated as a collateral

Clinical: Post-prandial pain, weight loss

Sono: Abnormal flow patterns, elevated velocities in CA or SMA. Prominently seen IMA

Venous Anatomy

- IVC is formed by the union of the common iliac veins
- Veins have same three layers as arteries, with the media being thinner in veins
- Renal veins drain into IVC. Left renal vein crosses anterior to aorta and posterior to SMA
- Hepatic veins last contribution to IVC (most superior)
- IVC terminates when draining into right atrium
- Normal IVC measures up to 2.5cm and varies in size with respiration
- Venous flow becomes more pulsatile as it gets closer to heart
- Portal venous system is unrelated to IVC system (pg 5)

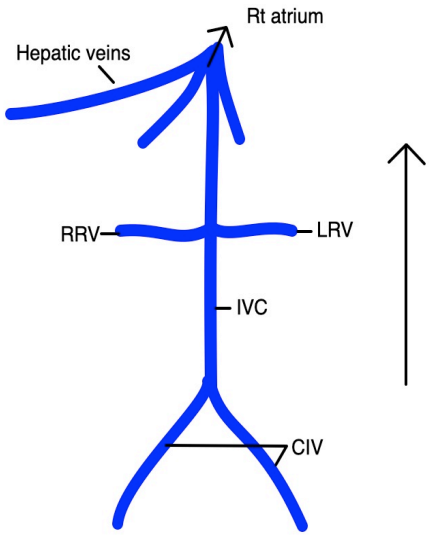

Venous Pathology

Hepatic vein and IVC enlargement

"Playboy bunny" sign. IVC >2.5cm and lack of respiratory variation. Caused by right-sided heart failure or any another way to describe a congested right atrium. Veins will enlarge if they cannot flow into where they are supposed to go.

IVC tumor

Related to renal cell carcinoma (hypernephroma) and Wilms tumor (nephroblastoma). Cancer invasion via the renal veins

*** if tumor in IVC, check kidneys for tumor!

IVC filter

Vena caval filter or Greenfield filter is placed in the infrarenal (below the renal veins) IVC. Purpose is to reduce risk of pulmonary embolism in high risk patients.

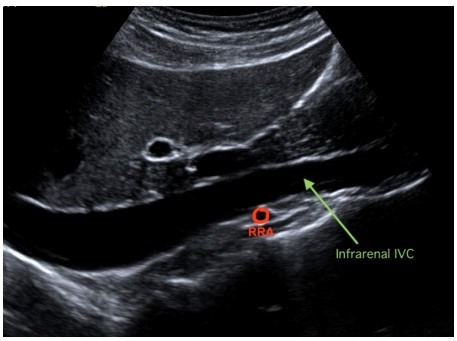

Common Problems to Identify

WHAT	WHERE
Nutcracker syndrome	Left renal vein
Tardus Parvus RA stenosis	Segmental artery
Post-prandial pain	SMA or Celiac
Solid renal mass	IVC by the renal artery
Filter	IVC or Infrarenal IVC
Caliper for AAA	Outer border/perpendicular